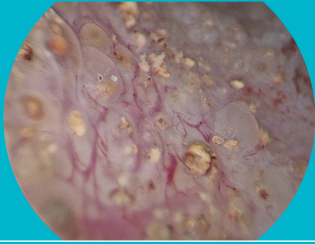
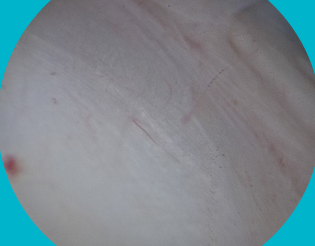

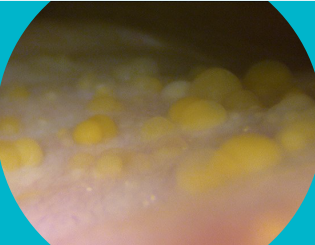
CONDITIONS OF THE TRIGONE



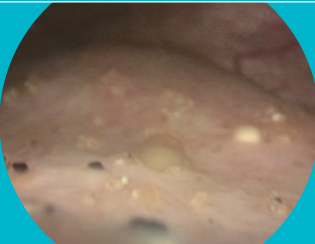
Calcified cystitis cystica and cystitis glandularis



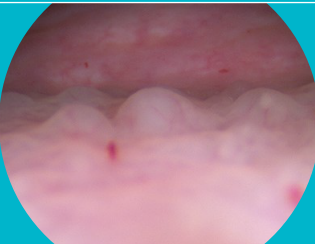Same patient after removal of cystitis cystica



Cystitis cystica of trigone

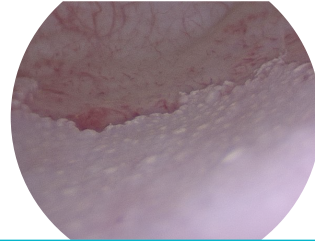


Cystitis cystica and cystitis glandularis

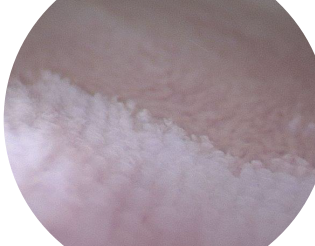

Follicular cystitis

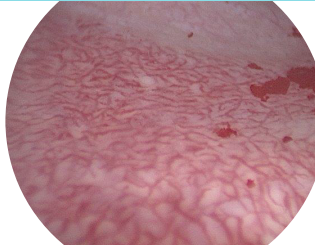CONDITIONS OF THE TRIGONE



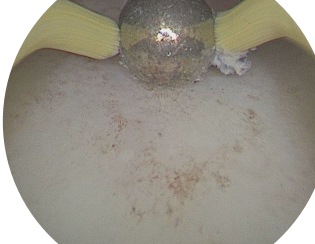Squamous Metaplasia of trigone



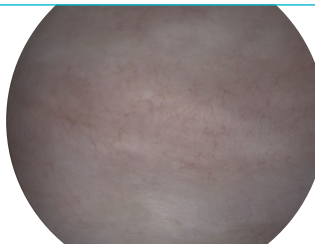
Squamous metaplasia



Hypervascularity of trigone

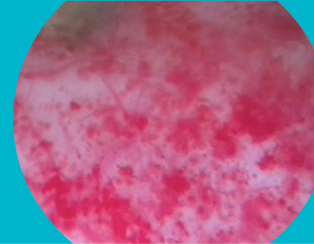

Trigone after roller ball diathermy

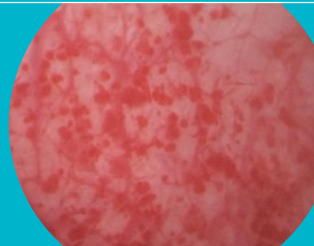


Normal Trigone 8 years after diathermy for cystitis cystica

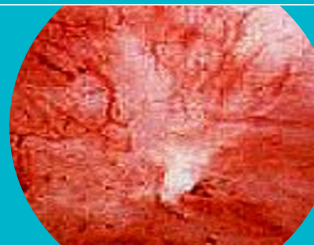CONDITIONS OF THE BLADDER



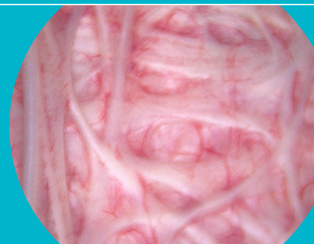Interstitial Cystitis of bladder



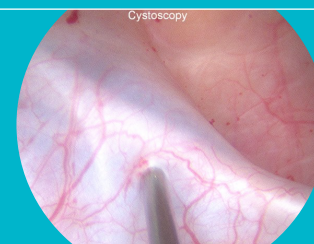
Interstitial Cystitis of bladder 2



Hunner's lesion of interstitial cystitis

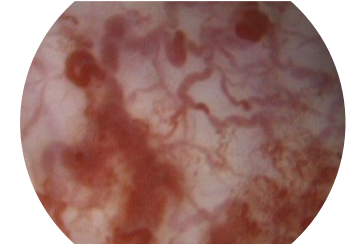


Bladder trabeculations

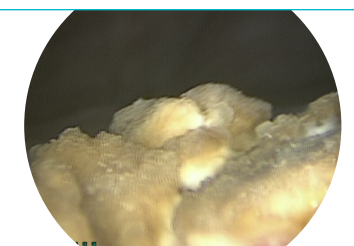

Botox injection into trabeculation

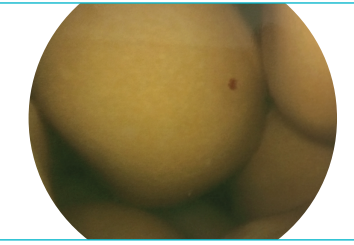
CONDITIONS OF THE BLADDER



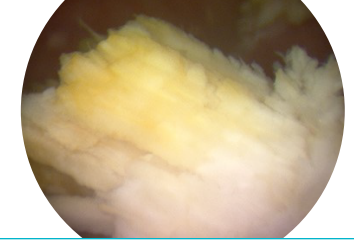
Radiation Cystitis



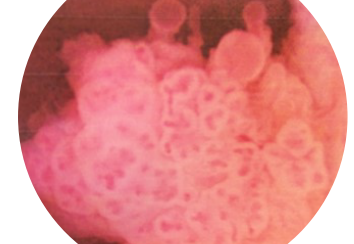
Bladder Stone



Bladder Stones

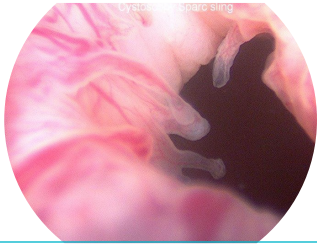

Calcification bladder wall

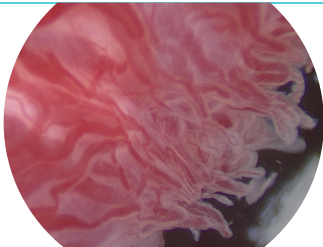


Bladder Tumour

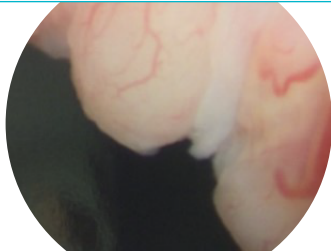CONDITIONS OF THE URETHRA



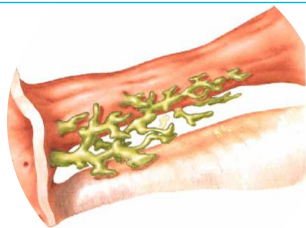
Winsbury White Fronds urethra



Winsbury-White fronds



Urethritis cystica of urethra



Glands around female urethra

TREATMENT OF CHRONIC CONDITIONS OF THE TRIGONE:

Although long-term antibiotics can be of help, many patients with chronic bladder infection symptoms may benefit from diathermy of the bladder trigone and removal of these chronically inflamed lumps on the trigone.

CHRONIC CYSTITIS

DIRK DRENT
UROLOGIST

www.uro.co.nz

33 Tawa Street, Melville, Hamilton
PO Box 6059, Urlich, Hamilton 3245

Telephone: 07-843-0017

Facsimile :07-843-0018

Mobile: 0274-314-367

EDI: gastroew

Email: dirk@uro.co.nz

www.uro.co.nz

